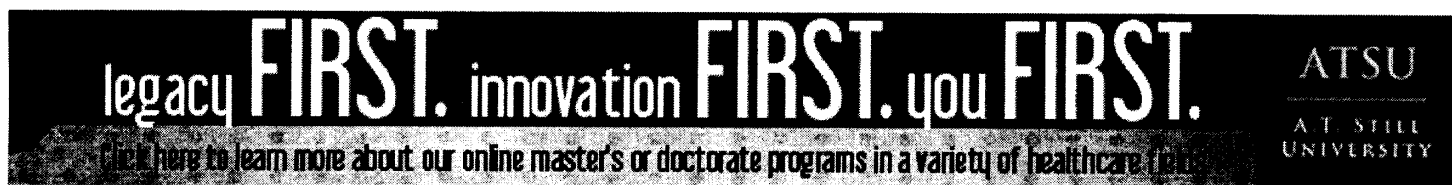


7-1-2011

## Preexcitation Syndromes

James F. Ginter  
*Aurora Cardiovascular Services*

Patrick Loftis  
*Marquette University, patrick.loftis@marquette.edu*



Click here  
for JAAPA  
author  
guidelines

Print This Article

<< [Return to Preexcitation syndromes](#)

## Preexcitation syndromes

James F. Ginter, MPAS, PA-C, Patrick Loftis, PA-C, MPAS, RN

July 12 2011

Earlier in this series, we discussed what happens when conduction between the atria and ventricles is delayed ([here](#), [here](#), and [here](#)). In preexcitation syndromes, we have the opposite of a block. Instead of being slowed or stopped, transmission of the electrical impulses between the atria and ventricles speeds up.

As discussed previously, a natural delay in conduction at the atrioventricular (AV) node allows the atria to contract fully before the ventricles depolarize and then contract. This results in efficient flow of blood through the heart and provides maximal cardiac output. In preexcitation syndromes, a bypass tract carries part of the transmission around the AV node. Because it is not being “held up” in the AV node, the signal gets through to the ventricles more quickly than normal.

Bypass tracts occur in less than 1% of the population and more often in males than females.<sup>1</sup> Several types of tracts have been discovered. The most common preexcitation syndrome is Wolff-Parkinson-White syndrome (WPW). It was first described in 1930 by three cardiologists: Louis Wolff, Sir John Parkinson, and Paul Dudley White, who recognized this pattern in 11 patients with arrhythmias.<sup>2</sup> In WPW, there is an accessory pathway known as the *bundle of Kent* that is most commonly located somewhere between the atria and ventricles. However, one or multiple pathways may be present. These are often described as left-sided (type A) or right-sided (type B).

Although definitive localization is not possible using ECG alone, some ECG findings may be helpful. In type A, there is a mostly positive (up-going) delta wave in lead V<sub>1</sub>, whereas in type B, there is a mostly negative (down-going) delta wave in V<sub>1</sub>. Definitive localization of the tract(s) requires an electrophysiologic study (EPS). Note that because of the configuration of the QRS complex, a type A

WPW may be confused with a right bundle branch block, right ventricular hypertrophy, or myocardial infarction (MI), and a type B WPW may be confused with left bundle branch block or MI.<sup>3</sup>

**Symptoms** Wolff-Parkinson-White syndrome by itself does not cause symptoms. However, patients with WPW are predisposed to other arrhythmias. The most common of these are paroxysmal supraventricular tachycardia (PSVT) and atrial fibrillation (AF). Rarely, the accessory pathway causes the AF to be so rapid that it can degenerate into ventricular fibrillation. A desire to prevent these arrhythmias and the symptoms associated with them often prompts patients to seek ablation therapy.

**ECG findings** In WPW syndrome, the part of the ventricle that is directly connected to the bundle of Kent is depolarized first, followed by depolarization of the rest of the ventricle through the normal pathway. This manifests as a short PR interval ( $<0.12$  sec), a characteristic delta wave (**Figure 1**), and QRS complexes wider than 100 milliseconds.

**Treatment** The definitive treatment for WPW is ablation therapy after localization, which requires an electrophysiologic study. The study is done by an electrophysiologist, who inserts a catheter through the groin and then feeds it into the atria. Localization requires special probes. Once found, the area is treated with electrocautery or another method to close the pathway permanently.

## ECG CHALLENGE

A 40-year-old male was seeing his primary care physician for periodic episodes of near-syncope. The patient had no medical history and was taking no medications. His father died at age 50 years of an unknown heart problem. Using a stepwise approach to analyze an ECG similar to the patient's (**Figure 2**), we see the following:

1. Is the ECG **regular**? Yes, the QRS complexes and P waves march out.

2. What is the **heart rate**? Find a QRS complex on or near a dark line:

**Method A:** Counting the large boxes, we see that there are about three large boxes before the next QRS complex. Three boxes would put the heart rate at about 100 beats per minute.

**Method B:** Approximately nine QRS complexes occur in 6 seconds (30 large boxes), which estimates the heart rate at  $9 \times 10 = 90$  beats per minute.

**Method C:** There are three large boxes between QRS complexes, which gives us  $300 \div 3 = 100$  beats per minute.

3. There is a **P wave** for every QRS complex, and all P waves look the same.

4. The **PR interval** spans about two small boxes, which is 0.08 seconds, and is shorter than the normal 0.12 to 0.2 seconds.

5. The **QRS complex** spans about three small boxes, which is 0.12 seconds. It also exhibits a negative delta wave in lead V<sub>1</sub>.

6. Some **ST-segment** elevation is visible in leads V<sub>2</sub> and V<sub>3</sub>. This could be a nonspecific finding, or it could suggest some ischemia in the anterior wall.
7. There is **T wave** inversion in lead III, which is a non-specific finding. This could indicate ischemia and should be evaluated further if it is a new finding.
8. There are **no U waves**.

**Making the diagnosis** The QRS complex on this ECG (which actually represents a fusion beat of both the abnormal and normal depolarization pathways) is widened to more than 100 milliseconds and has a characteristic delta wave. Based on the ECG findings, the diagnosis would be type B Wolff-Parkinson-White syndrome with nonspecific ST-segment elevation in leads V<sub>2</sub> and V<sub>3</sub>. The next step would be to refer the patient for EPS to evaluate the accessory pathway. Successful ablation of the abnormal pathway would produce resolution of the symptoms. In addition, a nuclear stress test would help to further evaluate the ST-segment elevation. **JAAPA**

Click on the **view full slideshow** link above to examine the figures in greater detail.

## REFERENCES

1. Thaler M. *The Only EKG Book You'll Ever Need*. 6th ed. Philadelphia, PA: Lippincott Williams & Wilkins; 2009:203.
2. Kulig J, Koplan BA. Wolff-Parkinson-White syndrome and accessory pathways. *Circulation*. 2010;122(15):e480-e483.
3. Esberger D, Jones S, Morris F. ABC of clinical electrocardiography: junctional tachycardias. *BMJ*. 2002;324(7338):662-665.