

11-11-2011

Right Bundle Branch Block

James F. Ginter
Aurora Cardiovascular Services

Patrick Loftis
Marquette University, patrick.loftis@marquette.edu

Right bundle branch block

[James F. Ginter, MPAS, PA-C](#), [Patrick Loftis, PA-C, MPAS, RN](#)

November 11 2010

Before we discuss bundle branch blocks, a review of normal cardiac conduction is warranted. In a normal heart, cardiac conduction begins with stimulus from the sinoatrial (SA) node. This firing of the SA node causes the atria to depolarize and contract simultaneously. During atrial depolarization, the stimulus continues downward to the atrioventricular (AV) node, where it is slowed, allowing for complete contraction of the atria. From the AV node, the stimulus travels through the His bundle and then on to the left and right bundle branches. In normal conduction, the bundle branches carry the stimulus downward at exactly the same speed to the Purkinje fibers of their respective ventricles such that the ventricles depolarize and contract at exactly the same time (**Figure 1**). This pathway is the most efficient way to provide maximal cardiac output: simultaneous contraction of the atria followed by simultaneous contraction of the ventricles.

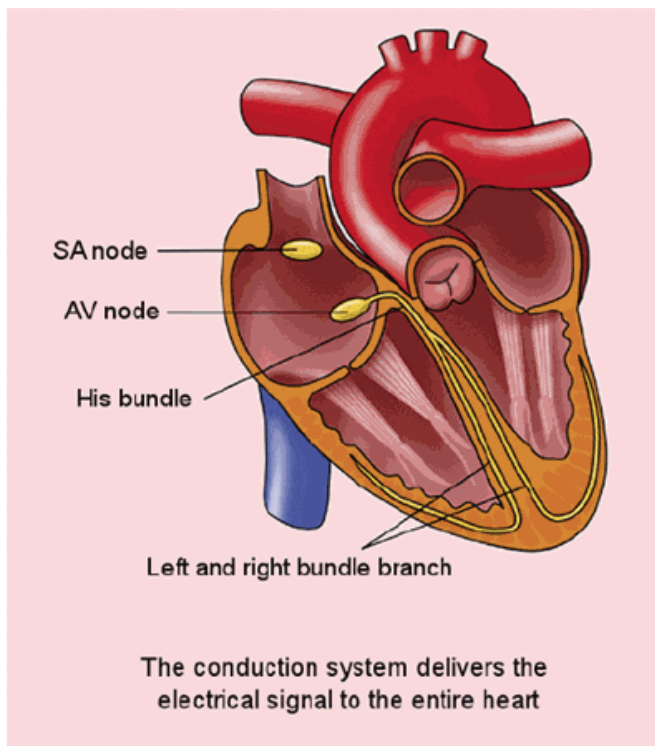


FIGURE 1. Normal conduction pathway (Purkinje fibers not shown)

Bundle branch blocks

A common disorder of the cardiac conduction system is a bundle branch block. Blocks can occur in the right bundle, the left bundle, or in a branch of the left bundle (fascicular block), or they may occur in combination.

Symptoms Right bundle branch block (RBBB) in and of itself does not cause symptoms. However, since the bundle branches are supposed to carry current to both ventricles at exactly the same time, a block may result in dyssynchrony, eg, depolarization and subsequent contraction occurring at different times in the two ventricles. Some patients tolerate this just fine, whereas those with heart failure or other underlying cardiac disease may not. A patient with heart failure who develops an RBBB block may exhibit worsening symptoms, such as dyspnea and edema. This is the reason that a bundle branch block (right or left) is one of the indications for placement of an implantable cardiac defibrillator or for cardiac resynchronization therapy in class III and IV heart failure.¹

Etiology A right bundle branch block can and often does occur in an otherwise normal heart. Other potential causes include myocardial infarction (MI), infection, pulmonary embolus (PE), and hypertension. Further workup may be based on the patient's other symptoms and comorbidities; there is no workup recommended specifically for RBBB.

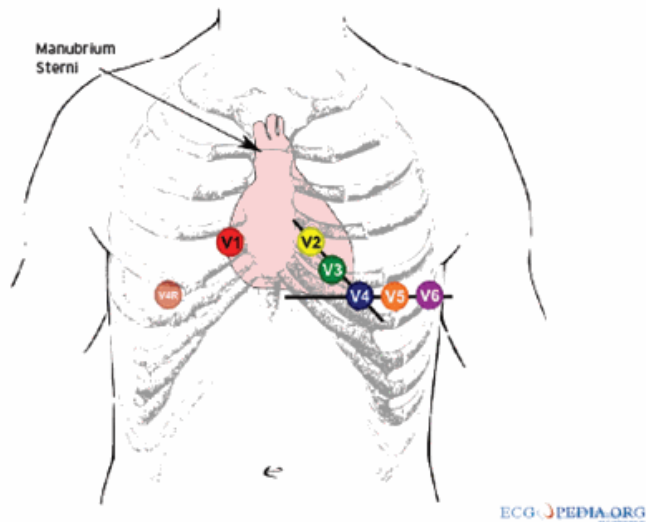


FIGURE 2. Chest leads in position for an ECG

ECG findings At the most basic level, a blockage in a bundle branch causes a delay in conduction. We know that bundle branch activity results in the simultaneous depolarization and contraction of the ventricles. We also know that this ventricular activity is manifested by the QRS wave on the ECG. So, we might expect the QRS wave to be prolonged if there is a bundle branch block, and this is exactly what happens. **The first rule of any bundle branch block is that the duration of the QRS complex must be greater than 120 milliseconds (three small boxes).** This basic criterion holds true for any type of bundle branch block; deciding which side the block is on requires a little more evaluation.

Occasionally, you will see an ECG that exhibits a QRS wave with a duration greater than 120 milliseconds but lacks other characteristics of a right or left bundle branch block. This finding represents a nonspecific intraventricular conduction delay (NSIVCD); it cannot be localized with the ECG alone.

Right bundle branch block An RBBB is exactly what its name suggests, eg, a blockage in the conduction of electricity through the right bundle. The results of this blockage are twofold: (1) a slowing in overall ventricular depolarization and (2) depolarization and contraction occurring at different times in the two ventricles. On the ECG, this dyssynchrony is manifested in either of the leads overlying the right ventricle (V₁ or V₂) (**Figure 2**) as a hump or “bunny ear” within the QRS complex (**Figure 3**).

This appearance is called an RSR' because the first upgoing deflection of the QRS is followed by an additional upgoing deflection known as R'. The appearance (morphology) or absence of the “bunny ear” is not important, only that there is an extra notch, or R'. Reciprocal changes are also seen as a slurred S wave in leads V₅ and V₆.

ECG challenge

A 79-year-old woman with a history of hypertension who was about to undergo an orthopedic procedure presented for evaluation. An ECG was obtained (**Figure 4**). No previous ECGs were available for comparison. The patient was taking atenolol 20 mg per day.

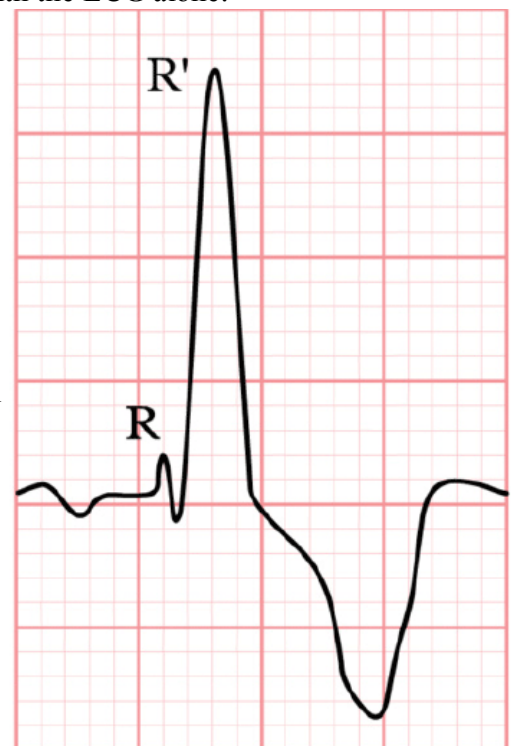

FIGURE 3. A hump or “bunny ear” in the QRS complex of lead V1

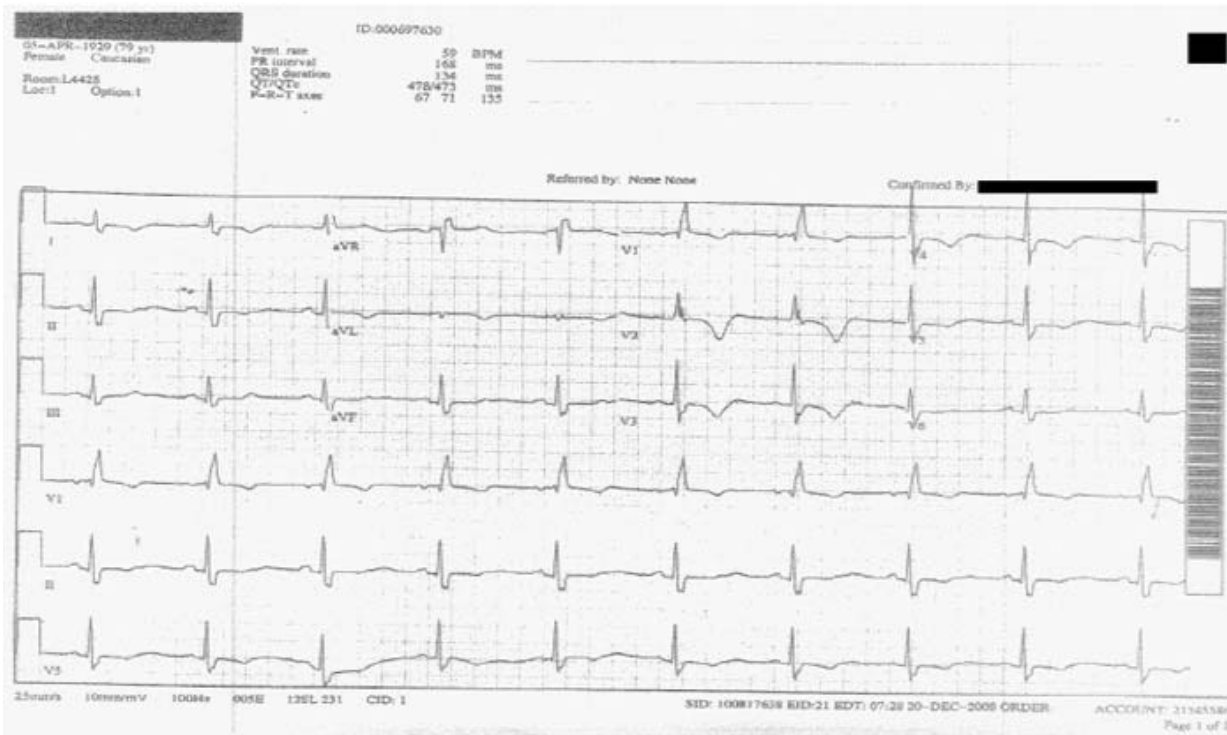


FIGURE 4. ECG of a woman with a history of hypertension

Stepwise analysis of the ECG

1. Is the ECG **regular**? Yes. The QRS complexes march out.
2. Determine the patient's **heart rate** by finding a QRS complex on or near a dark line.

Method A: There are approximately five large boxes between QRS complexes. That gives us a heart rate of 60 beats per minute.

Method B: There are about six QRS complexes in 6 seconds (30 large boxes), which estimates the heart rate 60 beats per minute (6×10).

Method C: Dividing 300 by the number of large boxes between R waves (5) gives us an estimated heart rate of 60 beats per minute.
3. There is a **P wave** for each QRS, and all P waves look the same.
4. The **PR interval** spans about four small boxes, which is 160 milliseconds. This is normal.
5. The **QRS complex** spans more than three small boxes (120 milliseconds), which is wider than normal. This finding may indicate a bundle branch block or a nonspecific intraventricular conduction delay. To distinguish between the two, we need to examine the QRS in leads V₁ and V₂. In lead V₁, there is a slurred R wave, and in lead V₂, there is a characteristic RSR'. Moving on to lead V₅, we see a notched S wave, and in lead V₆, we see a slurred S wave. All these findings indicate the presence of a right bundle branch block. If the widened QRS complex had been the only finding, we would have an NSIVCD.
6. **ST-segment deviation** is unreliable in the setting of a bundle branch block, as the block itself causes some changes here.
7. **T-wave inversion** is normally present in the setting of a bundle branch block and is also unreliable.
8. **No U waves** are present.

The patient had a right bundle branch block. Given her comorbidities, she underwent a stress test, which was negative for ischemia and showed a normal ejection fraction. The surgeon performed her orthopedic procedure without complications. Continued aggressive management of her hypertension was recommended. [JAAPA](#)

REFERENCES

1. Jessup M, Abraham WT, Casey DE, et al. 2009 focused update: ACCF/AHA guidelines for the diagnosis and management of heart failure in adults: a report of the American College of Cardiology Foundation/American Heart Association Task Force on Practice Guidelines: developed in collaboration with the International Society for Heart and Lung Transplantation. *Circulation*. 2009;119(14):1977-2016.

SUGGESTED READING

Thaler M. *The Only EKG Book You'll Ever Need*. 6th ed. Philadelphia, PA: Lippincott Williams & Wilkins; 2009:175-181.