Marquette University
e-Publications@Marquette

Physician Assistant Studies Faculty Research and Publications

Health Sciences, College of

4-23-2012

# Pericarditis

James F. Ginter
*Aurora Cardiovascular Services*

Patrick Loftis
*Marquette University*, patrick.loftis@marquette.edu

Published version. *Journal of the American Academy of Physician Assistants,* (April 2012). Permalink: www.jaapa.com/pericarditis/article/237665/". © American Academy of Physician Assistants. Used with permission.

# Pericarditis

James F. Ginter, MPAS, PA-C, Patrick Loftis, PA-C, MPAS, RN
April 23 2012

The pericardium is a fibrous sac made up of visceral and parietal layers that separates the heart from the other structures in the thorax. Inflammation of the pericardial sac is referred to as acute pericarditis.

Pericarditis can present in many ways depending on the cause. The major clinical manifestations of acute pericarditis include:[1]

- Chest pain that is typically sharp and pleuritic and improves with sitting up and leaning forward
- Pericardial friction rub that is best heard with the diaphragm over the left sternal border
- ECG changes with new widespread ST elevation
- Pericardial effusion

In patients with acute pericarditis, the ECG may evolve through as many as four stages of changes.[2] The typical progression of ECG changes in patients with acute pericarditis is described below:

- **Stage 1**, seen in the first hours to days, is characterized by a diffuse ST segment.
- **Stage 2**, typically seen in the first week, is characterized by normalization of the ST and PR segments.
- **Stage 3** is characterized by the development of diffuse T wave inversions; however, this stage is not seen in some patients.
- **Stage 4** is represented by normalization of the ECG or indefinite persistence of T wave inversions in chronic pericarditis.

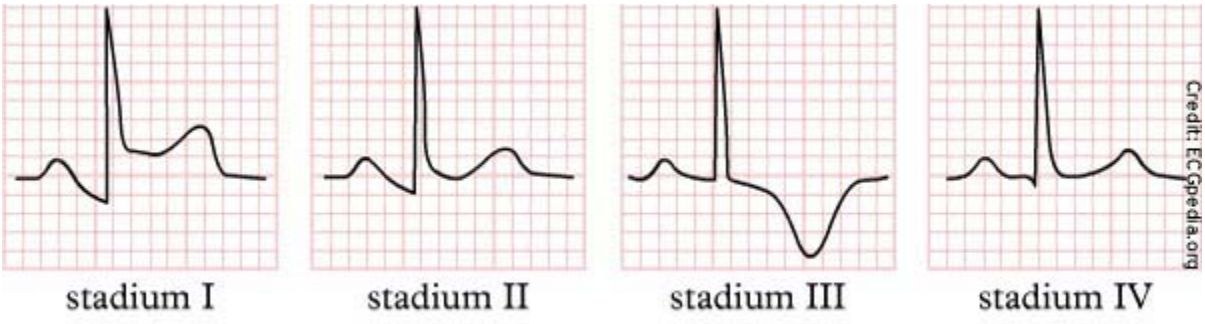


FIGURE 1. ECG showing stadia pericarditis

Both acute pericarditis and acute myocardial infarction can present with chest pain and elevations in cardiac biomarkers. However, the electrocardiographic changes in acute pericarditis differ from those in acute ST elevation myocardial infarction (STEMI) in the following ways:[3]

- The ST segment in acute pericarditis is elevated at the J point; elevation is rarely greater than 5 mm.
- The pericardium envelops the heart, and the ST-T changes are therefore more generalized, being present in V2-V6, I, aVL, II, and aVF.
- ST segment elevation and T wave inversions do not generally occur simultaneously in pericarditis.
- Q waves are generally not seen in pericarditis.

Treatment of acute pericarditis should be targeted to the underlying cause. Most cases of acute pericarditis are caused by idiopathic or viral infection. Patients are treated for a presumptive viral cause with nonsteroidal anti-inflammatory drugs (NSAIDs) and colchicine. Most patients with acute pericarditis can be managed successfully with medical therapy alone.

NSAIDs are the mainstay of treatment for acute pericarditis. Symptoms that fail to respond to NSAID therapy within 1 week suggest the cause is not idiopathic or viral. Most patients have prompt resolution of symptoms without recurrent pericarditis when treated with NSAIDS. Colchicine may reduce symptoms and decrease the rate of recurrent pericarditis.[4]

Most patients with acute pericarditis can be managed effectively with medical therapy alone. On occasion, patients may require invasive therapies such as pericardiotomy, pericardial window, or balloon pericardiotomy.

**ECG Challenge**

A 45-year-old male presents with sharp chest pain that has persisted off and on for the past several hours. There is no radiation of symptoms. The following ECG was obtained (**Figure 2**).

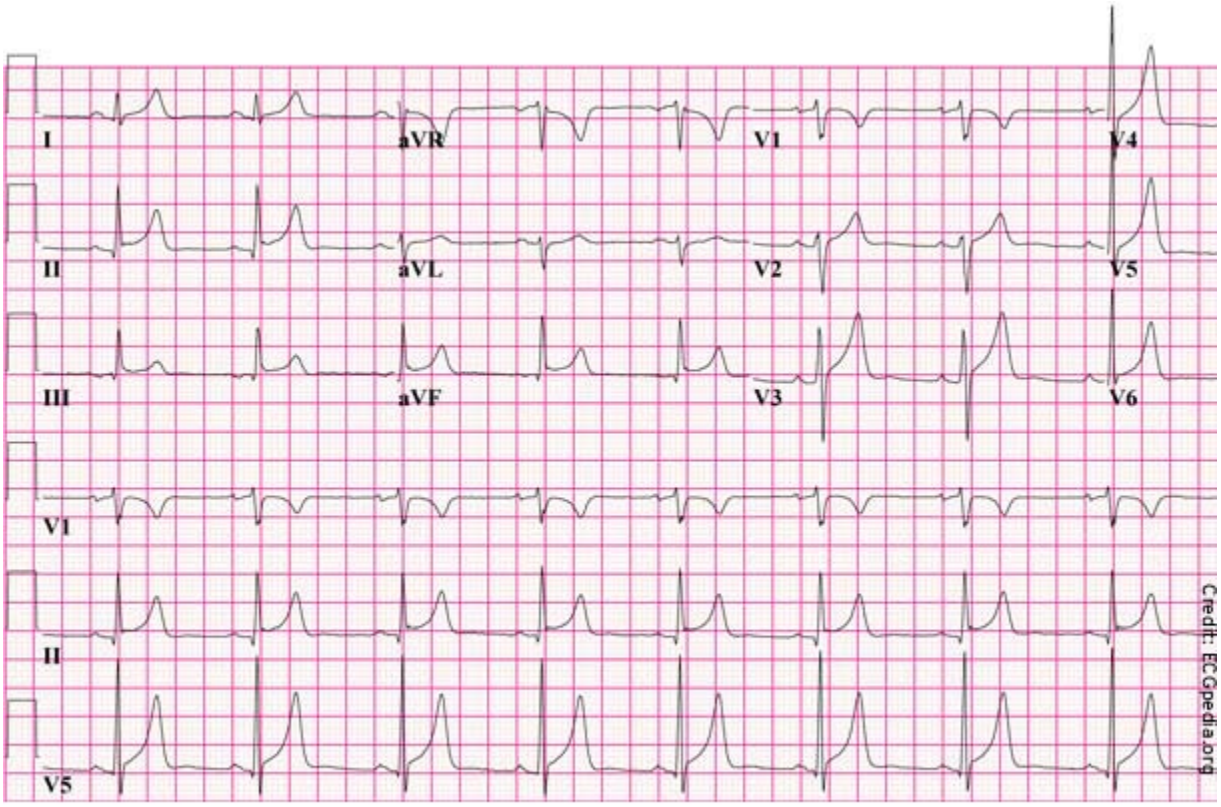


FIGURE 2. The patient's initial ECG

Is the ECG **regular**? Yes, the QRS complexes march out.

2. **What is the rate**? Find a QRS complex on or near a dark line. A) Counting the large boxes, we see that there are almost 5 large boxes before the next QRS complex. Five boxes would make the rate 60, so we will estimate it to be at 63 beats per minute. B) There are about 6 QRS complexes in 6 seconds (30 large boxes), which estimates the rate at 6 x 10 = 60 bpm. C) There are about 5 boxes in between the QRS complexes, making the rate 300/5 or about 60 bpm.

3. **There is a P wave** for every QRS, so this is sinus rhythm.

4. The **PR interval** is about 3 small boxes or 0.12 seconds. This is normal.

5. The **QRS complex** is about three small boxes, which is 120 milliseconds. This is normal.

6. There is difuse **ST segment elevation** here present in all the leads except for III, aVR, and V1.

7. There are **no U waves**.

**ECG Diagnosis**

The patient had acute pericarditis.

**REFERENCES**

1. Troughton RW, Asher CR, Klein AL. Pericarditis. *Lancet.* 2004;363(9410):717-727.

2. Spodick DH. Acute pericarditis: current concepts and practice. *JAMA.* 2003;289(9):1150-1153.

3. Permanyer-Miralda G, Sagristá-Sauleda J, Soler-Soler J. Primary acute pericardial disease: a prospective series of 231 consecutive patients. *Am J Cardiol.* 1985;56(10):623-630.

4. Lotrionte M, Biondi-Zoccai G, Imazio M, et al. International collaborative systematic review of controlled clinical trials on pharmacologic treatments for acute pericarditis and its recurrences. *Am Heart J.* 2010;160(4):662-670.